

Minimal Invasive Dentistry- A Systematic Respect For The Original Tissue.

Dr. Utkarsha R. Shelke¹, Dr. Vijaykumar L Shiraguppi², Dr. Bharat Deosarkar³,
Dr. Syed Mohammed Tayeeb⁴, Dr. Surekha Rathod⁵, Dr. Yashkumar Shah⁶

Post Graduate Student¹, Prof & HOD², Reader³, Senior Lecturer^{4,5}, Post Graduate Student⁶

Department of Conservative Dentistry & Endodontics, Saraswati Dhanwantari Dental College & Hospital
& Post Graduate Research Institute, Parbhani, Maharashtra, India

ABSTRACT : Minimally invasive procedures are a new way of professional care which is joined by dentistry as well. The conservation of healthy tooth structure is the goal of minimal intervention dentistry which focuses on prevention, remineralisation, and minimal dentist intervention also. Minimally invasive dentistry reaches the treatment objective using the least invasive surgical approach, with the removal of the minimal amount of healthy tissues. The concept includes- accurate diagnosis of caries, caries risk assessment and preservation to technical procedures in repairing restoration. This is to extend the lifetime of the restored tooth with as minimal intervention as possible. Also, in minimal invasive dentistry, dentists make use of long lasting dental materials, so the need for future repairs is reduced.

Keywords: Air abrasion, Laser, Minimal invasion, Remineralisation, Sealants

INTRODUCTION

Minimal Invasive Dentistry (MID) may be defined as the maximum preservation of healthy dental tissue.¹ Minimally invasive dentistry (MID) is based on the philosophy that integrates prevention, remineralisation and minimal intervention for the placement and replacement of restorations.²

In conservative dentistry, Minimal Invasive Dentistry includes:

1. Diagnosis of primary and secondary carious lesions
2. Evaluation of caries risk, prevention and progression
3. Repair of the restoration in place of replacement.¹

In dentistry, it was introduced in the late 1800's by Dr. G.V. Black, the father of modern dentistry. Among the paramount of his rules was the concept of "extension for prevention".² His idea was to remove the possibility of future decay on the surface of the tooth already present with caries. The proper restoration most commonly involves the removal of an appropriate amount of tooth structure, many a times more than what was decayed. As a result, this process involves destruction of a lot of healthy tooth.²

There are four basic principles suggested for the World Dental Federation that must be applied to

fulfill the properties of minimal invasive dentistry, which are:

1. Control of the disease by reduction in the cariogenic flora.
2. Remineralise early lesions.
3. Repair, rather than replace faulty restorations.³

Minimal operative dentistry is based on:

1. Early diagnosis of caries.
2. Individual caries risk assessment.
3. Classification of depth and progression of caries.
4. Reduction in the cariogenic bacteria to decrease further demineralization and cavitation.⁴

The main goal of minimal intervention is "prevention of extension" rather than "extension for prevention".⁴

Minimally-invasive treatment in dentistry was pioneered in⁵

1. 1970s by application of silver diamine fluoride
2. 1978 by Preventive resin restoration (PRR)
3. 1980s by Atraumatic restorative treatment (ART)
4. 1990s by Chemo-mechanical caries removal concept⁵

Minimal intervention approach

The MI approach includes:

- Early detection of caries
- Caries removal and restoration⁶

Caries diagnosis

Fundamental purpose of caries diagnosis is to be able to identify, detect and classify the lesions to select most appropriate intervention for the patient. It includes:

1. Caries risk assessment
2. Early detection of caries⁷

1. Caries risk assessment

“The probability of an individual for developing a given disease”.⁷

2. Early detection of caries

To stop caries activity as early as possible, future caries risk and present caries activity should be established.⁷

Various new diagnostic aids are as follows-

- i. Visual, tactile examination
- ii. Dental radiographs
- iii. Laser fluorescence
- iv. Fiber-optic transillumination
- v. Digital imaging fiber-optic transillumination
- vi. Ultraviolet illumination
- vii. Electronic caries detector
- viii. Dye penetration
- ix. Quantitative light-induced fluorescence (QLF)
- x. Ultrasound imaging
- xi. Endoscope / videoscope⁹

Minimal invasive radiography

Use of RVG instead of E speed films is recommended. As it has acceptable clarity with minimal exposure and it is also a great option for radiography in pregnant woman. In early stages, subsurface demineralization of the enamel occurs. As caries progresses into deeper structures of tooth, the enamel surface begins to cavitate. Once it begins, it is very difficult to control it. Whereas, there are possibilities to arrest and reverse the loss of mineralisation in carious lesions at an early stage.¹⁰ In non-cavitated lesion, remineralization can take place.¹¹

Prevention of caries includes:

- Decreasing the frequency of intake of refined carbohydrates
- Optimum plaque control
- Optimum salivary flow
- Conducting patient education.⁵
- Chlorhexidine and topical fluorides.¹²
- 38% silver di-amine fluoride helps in remineralization.¹²

Various Remineralising Agents used for minimal invasive techniques:

1. Casein Phosphopeptide- Amorphous Calcium Phosphate (CPP-ACP): CPP is a component of milk which has anticaries properties and the remineralisation effect of 0.5- 1.0%. Under acidic conditions CPP- ACP binds to the surface of the tooth and buffers the free calcium and phosphate ions, which increases its levels in plaque and maintains its supersaturation state which promotes remineralisation.¹³

2. Combination of CPP-ACP and fluoride: When CPP-ACP is combined with fluoride remineralising potential increases.¹³

3. Novamin: It is chemically known as calcium sodium phosphosilicate. when it comes into contact with water, saliva, or other body fluids its reactivity increases which releases calcium, phosphate, sodium and silicon ions which leads to formation of new hydroxycarbonate apatite.¹⁴

4. Resin infiltrant technology: It is combined with a caries remineralising system and reduce long-term restorative needs.¹⁵

5. Tri calcium phosphate: Tricalcium phosphate exists in two forms, alpha and beta. When human enamel is heated to high temperatures, alpha form of TCP is formed. To prevent unwanted interactions which fluorides, TCP particles can be coated with sodium lauryl sulphate or other surfactants.¹⁶

6. Nano hydroxyapatite: Since nano-hydroxyapatite is very biocompatible and bioactive material, it can be combined with caries remineralizing system.¹⁶

7. Enamelon: Enamelon consists of calcium and phosphate salts with sodium fluoride.¹⁵

Cavity designs for minimal intervention

Cavity preparation design for minimal intervention are-¹⁷

1. "**Tunnel Preparation**" is used when lesion is more than 2.5 mm below crest of marginal ridge and contact area may remain sound and marginal ridge may be quite strong. Access to lesion through occlusal surfaces should be limited in extent.¹⁷

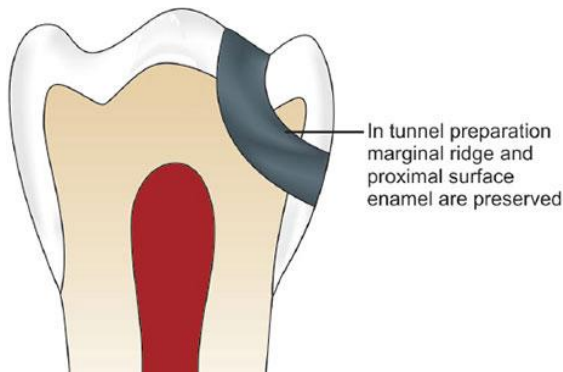


Fig. 1. Tunnel preparation

2. **"Slot cavity"** preparations are used when the lesion is less than 2.5 mm below crest of marginal ridge. Cavity design remains the same, the objective is to remove only that tooth structure which is broken beyond possibility of remineralization.¹⁷

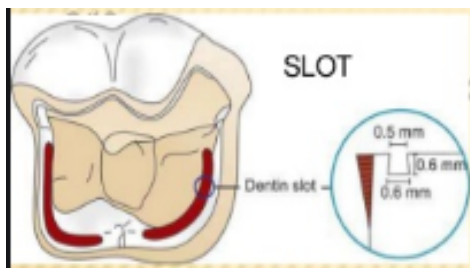


Fig. 2. SLOT cavity preparation

3. In **"Minibox"** cavity preparations, excavation of dentin lesion is same as normal excavation, design differs only in handling of enamel. In this, integrity of enamel wall needs to be preserved, and a full box need not be developed.¹⁷

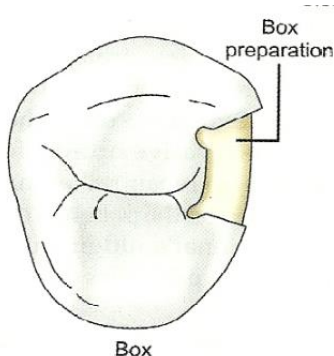


Fig. 3. "Minibox" cavity preparation

4. **"Full Box"** Cavity Preparation is indicated when enamel is in very poor condition and needs refining after removal of dentin lesion.¹⁷

5. **Saucer shaped** cavity is indicated for adhesive restorations. They are restored using smart materials i.e. Fluoride releasing composite, CPP ACP filler containing composite etc.¹⁷

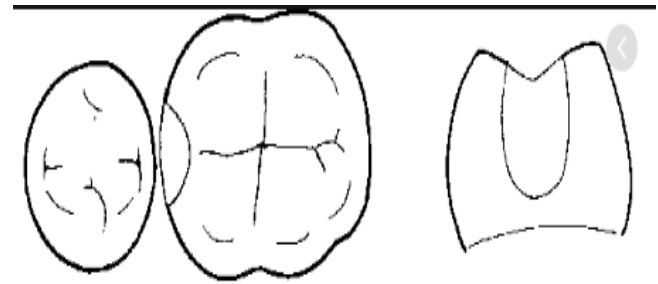


Fig. 4. Saucer shaped cavity preparation

MI Preparation techniques

1. Mechanical Rotary High/Low-Speed Bur
2. Atraumatic restoration
3. Air abrasion
4. Ultrasonics and Sono Abrasion
5. Air Polishing
6. Pit and fissure sealant
7. Chemomechanical caries removal.
8. Laser
9. Ozone Technology¹⁸

1. Mechanical Rotary High/Low-Speed Bur

Rotary burs are very useful as they easily cut through carious dentin to open up tubules deeper in the tissue.¹⁸

For minimal invasive dental treatment, two types of burs are available:

Fissurotomy Bur

Fissurotomy burs are available in three different shape and sizes:

- i) Fissurotomy Original,
- ii) Fissurotomy micro STF,
- iii) Fissurotomy micro NTF.¹⁸

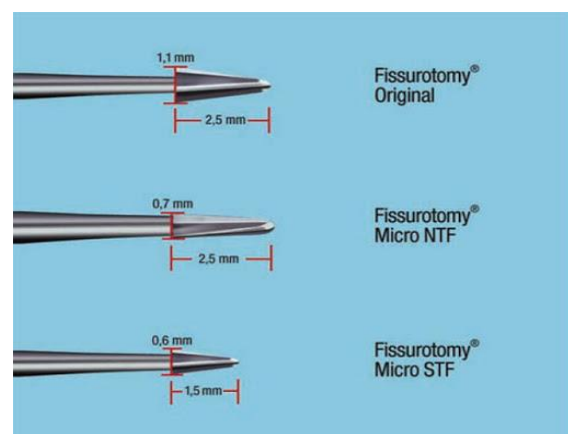


Fig. 5. Fissurotomy Bur

Fissurotomy original and fissurotomy micro NTF has a head length of 2.5 mm whereas fissurotomy micro STF has head length of 1.5 mm. They are helpful in minimal invasive dentistry as they have smaller dimensions which allows limits the preparation at the dentinoenamel junction.¹⁸

Polymer Bur

Polymer burs are also known as smart prep instrument or smart bur. They have an advantage as they can differentiate between the non-mineralizable and mineralizable dentine. These burs are available in ISO sizes 010, 014 & 018.¹⁸

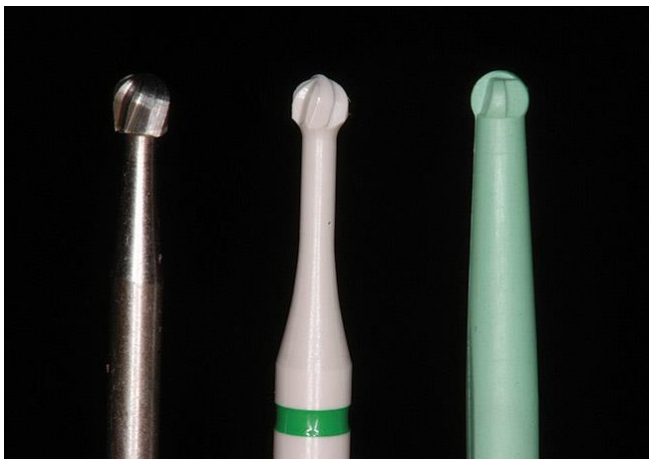


Fig. 6. Polymer Bur

Smart Bur

Smart burs are advantageous as they remove only soft carious dentin and not hard one. In this process excess cutting can be avoided as these burs blunt out when they come in contact with hard dentin. Smart burs come in no. 2, no. 4, and no. 6 with a different flute design. A new type of polymer i.e. medical grade polymer is used for making of instrument, which helps in prevention of excess cutting.¹⁸



Fig. 7. Smart Bur

2. Atraumatic restoration

Since, this technique requires no anaesthesia or electricity, it was originally developed for use in underdeveloped countries, in rural areas. First discovered in Tanzania in 1980s.⁵ Nowadays this technique is used worldwide, because of its “atraumatic” approach.¹⁹ It is based on principles of minimum intervention and minimum invasion. All the procedures are carried out only using hand instruments and adhesive restoration (GIC etc.). A combined preventive and curative treatment can be done in one appointment. ART is a non aerosol generating procedure and a timeless technique. When it was conceptualized there was no pandemic but now during covid-19 pandemic, it is highly in demand. But, it has some disadvantages too. It is not long lasting with an average life of 2-3 years. It has low wear resistance and low strength of GIC.¹⁹

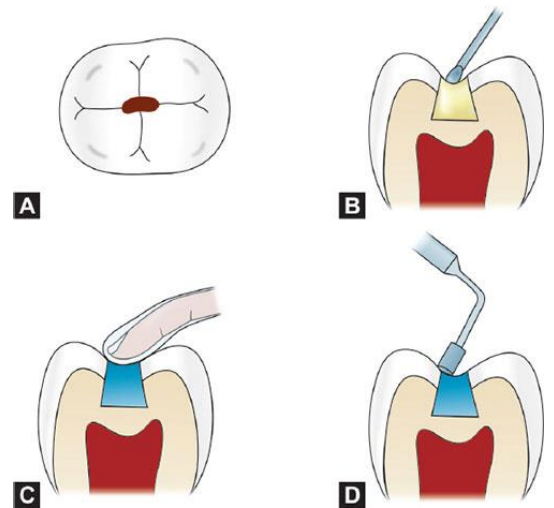


Fig.8. Atraumatic restorative treatment

3. Air abrasion

Air abrasion was originally developed by Robert Black in 1945 as an alternative pseudo-mechanical, nonrotating technique, used to remove decayed tissues. It uses kinetic energy for the removal of carious tooth structure.²⁰ A high speed narrow stream of aluminum oxide particles is directed against the surface that has to be removed.²¹ Advantage is that, it requires less time and energy consumption, no anaesthesia and does not produce vibrations and heat. Both simple stains and affected tissue can be removed easily. Alternative abrasive particles are polycarbonate resin or alumina hydroxyapatite mixtures which are more selective in removing carious dentin.²²

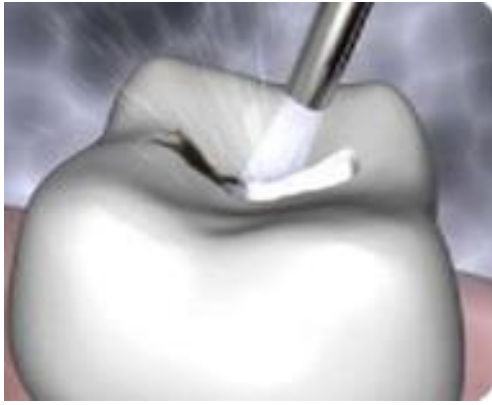


Fig.9. Air abrasion

4. Ultrasonics and Sono Abrasion

They are used in removal of proximal carious lesions in both posterior and anterior teeth.²³ It oscillates at a maximum frequency of 20-40 kHz with a average of about 6.5 kHz . A diamond coated tip oscillating is used to excise the dentin.²⁴ Sono-abrasion is used, which Sono abrasion offers excellent efficacy, quality and safety and is used for the selective preparation of enamel and dentin. The advantages include minimizing or eliminating noise, vibration, heat and pressure. The disadvantages are relatively low abrasion and high hub excursion of the tips, and weakening of the enamel rods with the associating cracks adjacent to the prepared sites.²⁴

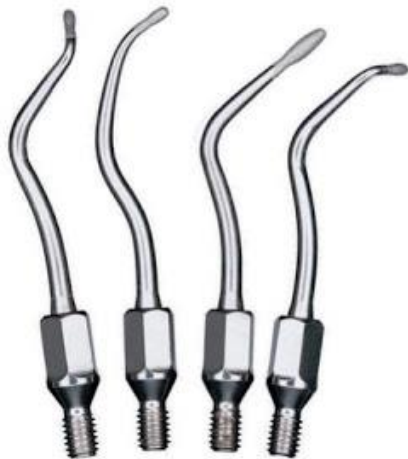

Fig. 10. Sono abrasion

5. Air Polishing

Works in a similar pattern as air abrasion but in air polishing, it produces high-pressure stream containing sodium bicarbonate which is projected on teeth surface, resulting in a cutting effect. Air polishing can cut dentin and cementum. It is used for removing stains and altered dentin.²⁵ It is done by the propulsion of abrasive particles with

a mixture of water and compressed air, along with handpiece.²⁶

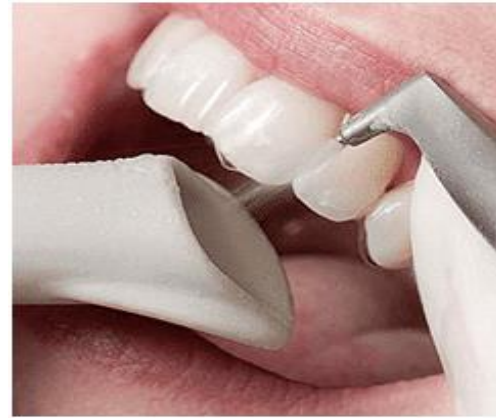

Fig. 11. Air Polishing

6. Pits and fissure sealants

Sealants modify pits and fissures into smooth surfaces which have been protected from bacterial colonization.²⁷ They help in arrest of non-cavitated enamel carious lesions in pits and fissures. Resin composites and glass-ionomer cements are generally used for this purpose.²⁸

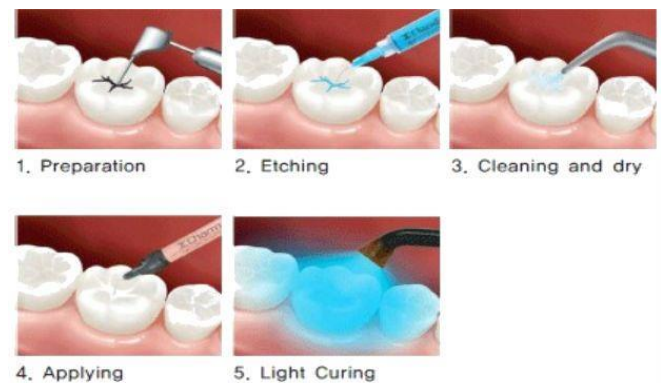

Fig.12. Pits and fissure sealants

7. Chemo-mechanical caries removal

Chemo-Mechanical Caries Removal involves the chemical softening of carious dentin and its removal by gentle excavation.²⁹

i. Caridex- It was developed by CM Habib from a formula, N- mono -chloroglycine and amino butyric acid. It involved intermittent application of preheated solution to carious lesion which causes disruption of collagen in carious dentine, thus facilitating its removal. It has unpleasant taste and lengthy procedure of approximately 10-15 minutes, in addition to the large volumes of solution needed, 200-500ml and also, that the delivery system was no longer commercially available, limited the use of caridex clinically.²⁹

ii. Carisolv

This material consists of a clear liquid (NaOCl) and a red gel (3 amino acids – Leucine Lysine, Glutamic acid, Carboxymethyl-cellulose gel, Na(OH)₂, and colouring agent) which are mixed together and applied on tooth. Average time required for complete caries removal is about 9-12 minutes and volume of gel utilized for this purpose is only 0.2-1.0 ml which is its advantage.³⁰



Fig. 13. Carisolv

iii. Papain Gel

It is available in syringe form and contains blue-coloured gel. It is composed of papain, chloramines, toluidine blue, salts, thickening vehicle which is responsible for bactericidal, bacteriostatic and anti-inflammatory properties.³¹

8. Laser

Lasers produce beams of coherent and very high-intensity light.³²

Lasers used for more selective hard tissue ablation include:

1. Erbium: Yttrium-aluminum-garnet (YAG) and Neodymium:YAG – Mid-infrared (IR) to IR emission
2. CO₂ laser – IR emission
3. Excimer lasers
4. Holmium lasers
5. Dye-enhanced laser ablation.³²



Fig. 14. Laser

9. Ozone Technology

Ozone has powerful antimicrobial property. Ozone helps in oxidization of biomolecules disrupting microbial cell wall in minutes leading to immediate cell lysis. 10 sec to 20 sec time period is sufficient to destroy microbes.³³

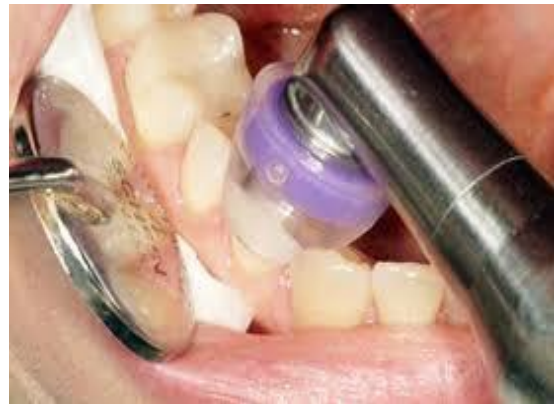

Fig. 15. Ozone Technology

CONCLUSION

It is obvious that it is time for a change in operative dentistry. It is impossible to imitate natural tooth structure, so retention of tooth structure is best way possible. The management of dental caries has evolved from G.V Black's "extension for prevention" to "prevention for extension" because of development of newer dental restorative materials and newer advances in adhesive dentistry which enables a better understanding of the caries process and the potential of teeth for remineralization and changes in caries prevalence and progression. "The preservation of that which remains is of utmost importance than the meticulous replacement of that which has been lost." Minimal invasive dentistry has the potential for dentists to adopt a more conservative approach to caries treatment and simultaneously offer patients a more friendly and health oriented treatment option.

REFERENCE

1. Mohanty D, Samir PV, Das RC, Sinha S. Minimal Invasive Dentistry- Evolution of Cavity Designing and its Restoration. World J Pharmaceutical Med Res 2017;3(5): 138-145.
2. D Ericson, E Kidd, D Mc Comb, I Mjor, MJ Noack. Minimally invasive dentistry-Concepts and Techniques in Cariology. Oral Health Prev Dent. 2003;1:59-72.

3. Black GV. A work on operative dentistry: The technical procedures in filling teeth. Chicago: Medico-Dental Publishing House. 1917;25:111–19.
4. Dixit K, Dixit KK, Pandey R. Minimal Intervention Tooth Preparation: A New Era of Dentistry. *J Dent Sci Oral Rehab* 2012;3(4):4–7.
5. Jingarwar MM, Bajwa NK, Pathak A. Minimal intervention dentistry—a new frontier in clinical dentistry. *J Clin Diagn Res.* 2014 Jul;8(7):ZE04.
6. Changing concepts in mechanical methods of cavity preparation Pradnya B V, Wavdhane M B, Pathak S D, Hardik Ideas Innov Tech.2018;4(6):717-736.
7. The effectiveness of seal-ants in managing caries lesions Griffin S O, Oong E, Kohn W. *J Dent Res.*2008;87:169-74.
8. Mickenautsch S. An introduction to minimum intervention dentistry. *Singapore Dent J.* 2005 Dec 1;27(1):1-6
9. An era from extention for prevention to constriction with conservation Jain S, Katiyar A. *Int J Dent Sci Innov.*2018;1(1):6-13.
10. Conservative Approach to Caries Excavation- A Chemo-Mechanical Method Madan N, Gandhi A. *Ind J Dent Sci.*2010;2(3):1-3.
11. Murdoch-Kinch CA, McLEAN ME. Minimally invasive dentistry. *J Am Dent Assoc.* 2003 Jan 1;134(1):87-95.
12. Murdoch-Kinch CA. Oral medicine: advances in diagnostic procedures. *J Calif Dent Asso.* 1999 Oct 1;27(10):773-80.
13. LJ Walsh. Contemporary technologies for remineralisation therapies: A review. *Int Dent SA.* 2009;11(6):6–16.
14. K Pradeep, PK Rao. Remineralizing agents in the non- invasive treatment of early carious lesions. *Int J Dent Case Reports.* 2011;1(2):73–84.
15. AM Kielbassa, J Muller, CR Gernhardt. Closing the gap between oral hygiene and minimally invasive dentistry: a review on the resin infiltration technique of incipient (proximal) enamel lesions. *Quintessence Int.* 2009;40(8):663–81.
16. Walsh LJ. Contemporary technologies for remineralization therapies: A review. *Int Dent SA.* 2009 Jan;11(6):6-16.
17. Mouradian WE. Ethical principles and the delivery of children's oral health care. *Ambulatory Pediatrics.* 2002 Mar 1;2(2):162-8.
18. Bansode Pradnya V, M. B. Wavdhane, Seema D. Pathak, Hardik. Changing concepts in mechanical methods of cavity preparation. *International Journal of Advance Research, Ideas and Innovations in Technology,* 2018; 4(6): 717-719.
19. BOITOR GC. PRINCIPLES AND MINIMALLY INVASIVE TREATMENT TECHNIQUES USED IN THE CURRENT TREATMENT OF DENTAL CARIES. *Acta Medica Transilvanica.* 2013
20. Abou Neel EA, Aljabo A, Strange A, Ibrahim S, Coathup M, Young AM, Bozec L, Mudera V. Demineralization–remineralization dynamics in teeth and bone. *Int J Nan medicine.*2016;11:4743
21. Tyas MJ, Anusavice KJ, Frencken JE, Mount GJ. Minimal intervention dentistry—a review* FDI Commission Project 1–97. *Int. Dent. J.* 2000 Feb;50(1):1-212.
22. Mohammadipour HS, Maghrebi ZF, Ramezani N, Ahrari F, Daluyi RA. The effects of sodium hexametaphosphate combined with other remineralizing agents on the staining and microhardness of early enamel caries: An in vitro

modified pH-cycling model. J. Dent. Res. 2019 Nov;16(6):398.

23. Madan N, Gandhi A. Conservative Approach to Caries Excavation – A Chemo-Mechanical Method. Ind J Dent Sci 2010;2(3):1–3.

24. Peters MC, McLean ME. Minimally invasive operative care. Contemporary techniques and materials: an overview. J Adhes Dent 2001;3(1):17–31.

25. Olivi G, Genovese MD, Caprioglio C. Evidence-based dentistry on laser paediatric dentistry: review and outlook. Eur J Paediatr Dent. 2009 Mar 1;10(1):2929-40.

26. Murdoch-Kinch CA, McLEAN ME. Minimally invasive dentistry. J Am Dent Assoc. 2003 Jan 1;134(1):87-95

27. Beiruti N, Frencken JE, Van't Hof MA, van Palenstein Helderma WH. Caries-preventive effect of resin-based and glass ionomer sealants over time: a systematic review. Community Dent Oral Epidemiol. 2006 Dec;34(6):403-9.

28. Fairag M M Naghi K M, Alshoubi E N. Minimally invasive dentistry Indo Am J P Sci.2009;06(1):1422-1428.

29. JA Beeley, H.K. Yip, A.G. Stevenson. Chemochemical caries removal: a review of the techniques and latest developments. Br Dent J. 2000;188(8):427–30.

30. Text Book of Operative Dentistry Sikri V K. New Delhi: CBS 2003.

31. Walsh L J. Contemporary technologies for remineralization therapies: A review . Int Dent S.2009; 11(6):6-16

32. Banerjee A, Watson TF & Kidd EA. Dentine caries excavation: A review of current clinical techniques. Br Dent J. 2000; 188(9): 476-482.

33. Suyash J, Alpana K. An Era from Extention for Prevention to Constriction with Conservation.

International Journal of Dental Science and Innovative Research. 2018; 1(1): 06 –13.

Corresponding Author

Dr. Utkarsha Shelke

SDDCH, Parbhani

utkarshashelke09@gmail.com

8329419904

How to cite this Article:

Shelke UR., Shiraguppi VL., Deosarkar B.,

Syed M.T., Rathod S., Shah Y.

Minimal Invasive Dentistry- A Systematic
Respect For The Original Tissue.

Journal of Interdisciplinary Dental
Sciences, July-Dec 2020;9(2):29-36